

Research report

Roles of hippocampal subfields in verbal and visual episodic memory



Andrea R. Zammit (PhD)^{a,*}, Ali Ezzati (MD)^{a,b}, Molly E. Zimmerman (PhD)^{a,c},
Richard B. Lipton (MD)^{a,b,e}, Michael L. Lipton (MD, PhD)^{d,f}, Mindy J. Katz (MPH)^a

^a Saul B. Korey Department of Neurology, Albert Einstein College of Medicine, Bronx, NY 10461, USA

^b Department of Neurology, Montefiore Medical Center, Bronx, NY 10467, USA

^c Department of Psychology, Fordham University, Bronx, NY 10458, USA

^d The Gruss Magnetic Resonance Research Center and Departments of Radiology, Psychiatry and Behavioral Sciences and the Dominick P. Purpura Department of Neuroscience, Albert Einstein College of Medicine, Bronx, NY 10461, USA

^e Department of Epidemiology and Population Health, Albert Einstein College of Medicine, Yeshiva University, Bronx, NY 10461, USA

^f Department of Radiology, Montefiore Medical Center, Bronx, NY 10467, USA

HIGHLIGHTS

- Neurocognitive tests tapping specific HC subfields can help target at-risk individuals.
- Subiculum was associated with verbal and visual episodic memory.
- CA1 was associated with verbal and visual episodic memory.
- No other subfields were associated with verbal or visual episodic memory.
- Our results suggest that CA1 and subiculum are responsible for retrieval.

ARTICLE INFO

Article history:

Received 26 July 2016

Received in revised form

13 September 2016

Accepted 15 September 2016

Available online 16 September 2016

Keywords:

Hippocampal subfields

Subiculum

CA1

Visual episodic memory

Verbal episodic memory

Older adults

ABSTRACT

Introduction: Selective hippocampal (HC) subfield atrophy has been reported in older adults with mild cognitive impairment and Alzheimer's disease. The goal of this study was to investigate the associations between the volume of hippocampal subfields and visual and verbal episodic memory in cognitively normal older adults.

Methods: This study was conducted on a subset of 133 participants from the Einstein Aging Study (EAS), a community-based study of non-demented older adults systematically recruited from the Bronx, N.Y. All participants completed comprehensive EAS neuropsychological assessment. Visual episodic memory was assessed using the Complex Figure Delayed Recall subtest from the Repeatable Battery for the Assessment of Neuropsychological Status (RBANS). Verbal episodic memory was assessed using Delayed Recall from the Free and Cued Selective Reminding Test (FCSRT). All participants underwent 3T MRI brain scanning with subsequent automatic measurement of the hemispheric hippocampal subfield volumes (CA1, CA2-CA3, CA4-dente gyrus, presubiculum, and subiculum). We used linear regressions to model the association between hippocampal subfield volumes and visual and verbal episodic memory tests while adjusting for age, sex, education, and total intracranial volume.

Results: Participants had a mean age of 78.9 (SD = 5.1) and 60.2% were female. Total hippocampal volume was associated with Complex Figure Delayed Recall ($\beta = 0.31, p = 0.001$) and FCSRT Delayed Recall ($\beta = 0.27, p = 0.007$); subiculum volume was associated with Complex Figure Delayed Recall ($\beta = 0.27, p = 0.002$) and FCSRT Delayed Recall ($\beta = 0.24, p = 0.010$); CA1 was associated with Complex Figure Delayed Recall ($\beta = 0.26, p < 0.002$) and FCSRT Delayed Recall ($\beta = 0.20, p = 0.025$).

Conclusions: Our findings confirm previous research on the specific roles of CA1 and subiculum in episodic memory. Our results suggest that hippocampal subfields have sensitive roles in the process of visual and verbal episodic memory.

© 2016 Elsevier B.V. All rights reserved.

1. Introduction

The association between the hippocampus and episodic memory is well established [1–4]; however, within the hippocampus,

* Corresponding author.

E-mail address: Andrea.Zammit@einstein.yu.edu (A.R. Zammit).

the roles of task-specific structures are still emerging, and only a few studies have investigated the association between hippocampal subfields and psychometric tests of memory in healthy older adults.

Hippocampal (HC) subfields include the cornu ammonis (CA1, CA2–3), CA4-dente gyrus (DG), the presubiculum and the subiculum. Previous research suggests that CA2, CA3, and DG are input structures, responsible for encoding, while the CA1 and subiculum are output structures, responsible for retrieval [5–9]. fMRI studies have further suggested specialized function for each subfield in hippocampal formation. Zeineh et al. [8] used a face-name associated task to study mnemonic processing in 10 healthy young adults; results showed that the CA2, CA3 and DG were involved in encoding whereas the subiculum showed more activation during recall, thus suggesting a double dissociation of activation patterns and tasks. In a similar experiment, Nauer et al. [9] assessed 34 healthy young adults on their working memory abilities for visuospatial information using complex visual outdoor scenes in delayed match-to-sample (DMS) tasks; results in this study showed that the hippocampal subfields CA1, CA3, DG and subiculum remained activated well into the delayed period, suggesting an ongoing mechanism of long-term information processing. Nauer et al. [9] refer to this as “ongoing encoding”, in which the immediate and delayed tasks are explained as one continuous process of activity reflecting ongoing encoding of stimuli.

Structural MRI studies have also shown these associations in case-control studies [10–12]. Muller et al. [12] explored verbal episodic memory using the California Verbal Learning Test II (CVLT-II) in individuals with temporal lobe deficits and healthy controls; they found that immediate verbal recall was associated with larger CA3 and DG volumes, while delayed verbal recall was associated with larger CA1 volumes. They also found similar results in another study using the same test on cognitively impaired older adults [11]. Research has also shown that CA1 volume declines with increasing age [13], and that compared to age-matched controls, Alzheimer's disease (AD) subjects show more atrophy in the CA1 and subiculum [14,15]. CA1 has also been associated with delayed verbal recall in AD [10], further suggesting CA1's role in retrieval that is associated with AD [15]. These findings have been extended to younger healthy adults in a study [16] that applied structural MRI to the study of hippocampal formation in younger adults; results showed that CA1, CA2/CA3 and DG played significant roles in verbal and visual memory retrieval.

In this manuscript, we assess the relationships of HC subfield volume with standardized neuropsychological tests of visual and verbal memory. Identifying neurocognitive measures that tap onto hippocampal subfields may provide a more efficient method of targeting individuals at risk of AD. Psychometric tests that are associated with specific hippocampal subfields may suggest atrophy and consequently ensure a more proactive approach of referring at-risk individuals for imaging procedures and early diagnosis. Thus, the aim of our study was to explore the role of hippocampal subfields in delayed verbal and delayed visual recall in a sample of community-dwelling older adults without dementia. We hypothesized that CA1 and subiculum would be associated with performance on tests of visual and verbal memory recall.

2. Methods

2.1. Sample

This cross-sectional study was conducted on a subset of 133 older adults from the Einstein Aging Study (EAS). The EAS study design and methods have been described previously [17]. Briefly, the EAS is an ongoing community-based volunteer sample of indi-

viduals over the age of 70 living in the Bronx, New York. Participants are systematically recruited from Medicare and from voter registration lists from Bronx County, New York City Board of Elections. Participants with visual and/or auditory impairment that interfere with neuropsychological testing, psychiatric symptomatology that interferes with test completion, non-English speakers, a nonambulatory status, and a dementia diagnosis were excluded from the study. In addition, participants did not participate in the study if they were ineligible for an MRI (e.g. due to metallic implants, claustrophobia, etc.). Written informed consent was obtained on their first clinical visit. The study protocol was approved by the local institutional review board. In this study, we only selected participants who have participated in MRI studies between July 2011 and October 2014.

2.2. Visual and verbal episodic memory assessment

We used two tests that contained three measures of visual episodic memory:

- i) Complex Figure subtest from the Repeatable Battery for the Assessment of Neuropsychological Status (RBANS) – copy and delayed recall [18]: This test assesses immediate and delayed visual and spatial ability and visual episodic memory and is relatively language free. The first part of this test involves the immediate free-hand copying of a very detailed line drawing. In the second part, which is the delayed part, the participant is required to recall and reproduce the figure from memory after a 20 min delay. Scores are based on accuracy of drawing and placement. Possible scores range from 0 to 20 for each test condition. This test is frequently used to test for dementia or neuropsychological impairment. In this study we only assessed the delayed condition since our interest is in visual episodic memory.
- ii) The Free and Cued Selective Reminding Test (FCSRT) [19] is an episodic memory test, which includes learning of 16 pictures by identifying and naming each picture. It also consists of three trials of immediate free recall, each of which is followed by cued recall in which a category cue is given to the subject to facilitate recall of the items not freely recalled. It also consists of a delayed free recall trial given after a 20 min delay. Delayed free recall (range 0–16) was used in these analyses.

2.3. MRI image processing

Imaging was performed using a 3.0T MRI scanner (Achieva Quasar TX; Philips Medical Systems, Best, the Netherlands) with a 32-channel head coil (Sense Head Coil; Philips Medical Systems, Best, the Netherlands). T1-weighted whole-head structural imaging was performed using sagittal three-dimensional magnetization-prepared rapid acquisition gradient echo (MP-RAGE) with TR/TE 9.9/4.6 ms; 240 mm² FOV; 240 × 240 matrix; partition thickness, 1 mm; and parallel acceleration factor 2.0. Furthermore, a 3D T2-weighted fluid-attenuated inversion recovery (T2W-FLAIR) acquisition was obtained with the following pulse sequence parameters: TR/TE/TI 11000/120/2800 ms; 240 × 240 mm FOV; 240 × 240 matrix; 1 mm partition thickness and parallel acceleration factor 2.0.

MRI data was processed using the FreeSurfer software package (<http://surfer.nmr.mgh.harvard.edu/>). Image processing methods in the EAS have been previously described in detail [20]. Briefly, the processing stream starts with a hybrid watershed algorithm, which removes non-brain tissue, automated transformation to the Talairach reference space and segmentation of the subcortical white matter and deep gray matter. All volumes including cortical GM volume, total cerebral WM volume, ventricular volume, and total hippocampal volume (HV) were segmented using FreeSurfer's

Table 1

Sample characteristics, including correlations between hippocampal subfields and Complex Figure Delayed Recall and Free and Cued Selective Reminding Test Delayed Free Recall.

Variables and units	Total sample (n = 133)	Complex Figure Delayed Recall		FCSRT Delayed Free Recall	
		r	p-value	r	p-value
Age, years (SD)	78.9 (5.1)	−0.23	0.008	−0.13	0.153
Males (%)	45 (39.8)	−0.13	0.150	0.11	0.260
Education, years (SD)	14.4 (3.4)	0.19	0.028	−0.00	0.990
White (%)	60 (53.1)	0.04	0.620	0.01	0.892
Mini Mental State Examination	26.5 (1.7)	−0.36	<0.001	−0.25	0.004
R Bans Complex Figure – Copy (SD)	17.4 (2.0)	0.32	<0.001	−0.06	0.487
R Bans Complex Figure – Recall (SD)	11.6 (3.8)	–	–	0.37	<0.001
FCSRT delayed free recall	25.1 (9.3)	0.37	<0.001	–	–
Total hippocampal volume, cm ³ (SD)	6.5 (8.1)	0.30	0.001	0.23	0.008
CA1, cm ³ (SD)	0.6 (7.2)	0.28	0.001	0.20	0.023
CA2/3, cm ³ (SD)	0.1 (2.1)	0.19	0.030	0.12	0.158
CA4/DG, cm ³ (SD)	0.9 (1.2)	0.17	0.049	0.13	0.126
Pre-subiculum, cm ³ (SD)	0.7 (1.02)	0.20	0.018	0.16	0.066
Subiculum, cm ³ (SD)	0.1 (1.3)	0.28	0.001	0.23	0.008
Total intracranial volume, cm ³ , (SD)	1358 (213)	0.17	0.051	−0.09	0.300

standard segmentation procedure using a probabilistic brain atlas [21]. Additionally, for each subject, the estimated intracranial volume (TICV) was calculated by the procedure described by Buckner et al. [22]. Subsequently, we performed automated subfield segmentation of the hippocampus using another procedure within the FreeSurfer suite. This procedure uses Bayesian inference and a probabilistic atlas of the hippocampal formation, which is based on manual delineations of subfields in T1-weighted MRI scans from a number of different subjects [23]. Using this method, seven subfield volumes were calculated for each side of the hippocampus: CA1, CA2-3, CA4-DG, presubiculum, subiculum, fimbria, and hippocampal fissure. The larger subfields are shown to correlate well with manual volume estimates, with an average dice coefficient of around 0.7 for CA1, CA2-3, CA4-DG, presubiculum, and subiculum [23]. Thus, for the purpose of this study, we chose larger subfields of CA1, CA2-3, CA4-DG, presubiculum, and subiculum due to their strong reliability of measurement. Automated volume estimates of these subfields are shown to correlate well between different MRI scanners [24]. Segmentation results were also visually inspected for errors in all datasets, but no manual edits were needed.

2.4. Statistical analysis

Statistical analyses were conducted using IBM SPSS Statistics for Windows, Version 22.0 (Armonk, NY: IBM Corp). In order to decrease Type I error by performing multiple comparisons, we combined left and right hippocampal subfields. Pearson correlation coefficients were utilized to examine associations between visual and verbal episodic memory tests and hippocampal volume including hippocampal subfields (CA1, CA2/3, CA4/DG, presubiculum, subiculum). Separate linear regression analyses were performed to examine hippocampal subfields as independent variables and delayed visual and verbal recall tests as dependent variables. Age, gender, race, education and TICV were used as potential covariates. We also used a Sidak correction [25] factor with an adjusted p-value of 0.01 for the hippocampal subfields (alpha = 0.05, five HC subfields). Subfields that were significantly associated with visual and verbal episodic memory were then analyzed for laterality.

3. Results

3.1. Demographic and sample characteristics

The mean age of the sample was 78.9 years, 39.8% were male, and 60% were Caucasian. Average total number of years in education was 14.4 years. Global cognitive function, as measured by

the Mini Mental State Examination was on average 26.5 (SD = 1.7). The mean scores on the Complex Figure Delayed Recall conditions were 11.6 (SD = 3.8). The mean score on the delayed recall from the FCSRT was 11.0 (SD = 3.7). Sample characteristics, visual and verbal episodic memory, and MRI-derived volumes of hippocampal sub-regions are presented in Table 1.

3.2. Correlational analysis

In correlational analyses (Table 1), age correlated negatively with Complex Figure Delayed Recall, and FCSRT Delayed Recall. Education correlated positively with Complex Figure Delayed Recall but was not significantly linked with FCSRT Delayed Recall. Total hippocampal volume was positively associated with both Complex Figure Delayed Recall ($r=0.31$, $p<0.001$) and FCSRT Delayed Recall ($r=0.23$, $p=0.008$). Volumes of all hippocampal subfields were directly correlated with performance on Complex Figure Recall and FCSRT Delayed Recall (Figs. 1 and 2).

3.3. Hippocampal volumes and visual and verbal memory

In linear regression analysis adjusted for age, sex, race, years of education, and TICV, total HV was positively associated with Complex Figure Delayed Recall ($\beta=0.31$, $p=0.001$) and FCSRT Delayed Recall ($\beta=0.27$, $p=0.007$).

Table 2 shows that within the hippocampal subfields, larger CA1 was associated with Complex Figure Delayed Recall ($\beta=0.26$, $p=0.002$) and with FCSRT Delayed Recall ($\beta=0.20$, $p=0.025$). The subiculum showed a positive independent association with Complex Figure Delayed Recall ($\beta=0.27$, $p=0.002$) and FCSRT Delayed Recall ($\beta=0.24$, $p=0.010$). Figs. 1 and 2 illustrate these results.

4. Discussion

In this cross-sectional study we found strong associations between total hippocampal volume and the performance on tests of visual and verbal episodic memory. Within the hippocampal structure, CA1 and subiculum were strongly associated with both visual and verbal episodic memory as represented by Complex Figure Delayed Recall and FCSRT Delayed Recall. Specifically, smaller CA1 and smaller subiculum were associated with poorer performance on both these tests.

Within the hippocampus, the subiculum is the main output component, projecting CA1's information to cortical and subcortical targets [26]. Previously, the subiculum has either been given little attention in the literature or treated as an ambiguous set of

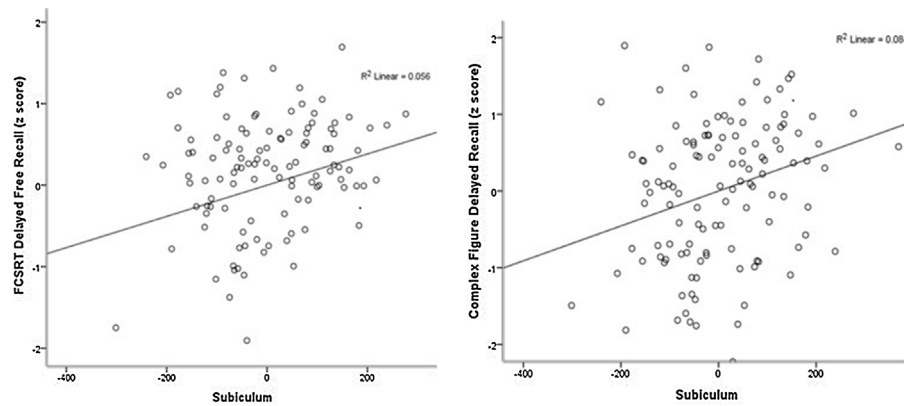


Fig. 1. Figures displaying correlation between subiculum and Complex Figure Delayed Recall and Free and Cued Selective Reminding Test Delayed Free Recall.

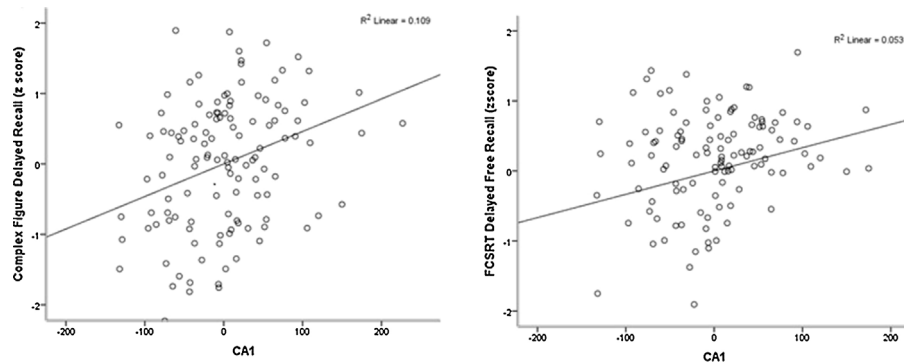


Fig. 2. Figure showing relationship between CA1 and Complex Figure Delayed Recall and Free and Cued Selective Reminding Test Delayed Free Recall.

Table 2

Linear regression models for the effect of hippocampal subfields on Complex Figure Delayed Recall and Free and Cued Selective Reminding Test Delayed Free Recall.

Hippocampal subfields	Figure Delayed Recall			FCSRT Delayed Free Recall			
	β	t	p	β	t	p	p
CA1	0.26	3.13	0.002	0.20	2.67	0.025	0.025
CA2/CA3	0.16	1.92	0.058	0.11	1.28	0.204	0.204
CA4/DG	0.17	2.02	0.045	0.13	1.41	0.160	0.160
Pre-Subiculum	0.17	1.92	0.057	0.16	1.80	0.074	0.074
Subiculum	0.27	3.12	0.002	0.24	2.63	0.010	0.010

Note: FCSRT = Free and Cued Selective Reminding test. Models adjusted for age, sex, education, total intracranial volume. Corrected for multiple testing ($p < 0.01$ was considered statistically significant). Bold indicates significant associations.

structures [27]; however, recently some focus has been attributed to it due to its emerging importance in spatial processing and performance [26,28], delayed verbal recall [29], and visual memory [8,9]. The subiculum encodes a representation of task relevant information for a relatively short time, whereas the CA1 cells become progressively engaged in retrieval processes [26]. Studies on rodents have further shown that CA1 and subiculum also work conjointly to encode information in visual delayed activities [30]. In human studies, subiculum and CA1 results also suggest involvement in immediate and delayed visual memory tests [8,9,16] and delayed verbal episodic memory tests [29]. Our results highlighting an association between verbal and visual episodic memory and CA1 and subiculum are in line with previous findings on increased CA1 and subiculum activity during delayed periods of visual [9,16,29,30] and verbal tasks [29]. This further enforces the hypothesis that CA1 and subiculum structures in the hippocampus are responsible for retrieval processes. We urge other researchers to further expand on these findings by using tests of spatial episodic memory to find out if results are replicated in this cognitive domain, and if laterality is

present in other tasks of spatial episodic memory that are known for their association with the hippocampus [31]. Studying the hippocampus in a detailed approach across age groups will help to sensitively map its distinct functions; in the case of pathology and cognitive decline this approach also helps target more selectively specific areas that are sensitive to atrophy and impairment.

Studies investigating hippocampal subfields in relation to AD have consistently shown that the CA1 and subiculum are the most affected areas [13,14,32,33], with slight disagreements on whether the neuronal loss is also significant in presymptomatic AD [14]. Some studies have shown that conversion from cognitively normal to MCI is associated with hippocampal atrophy specific to the subiculum and CA1 three years prior to a diagnosis, with conversion from MCI to AD showing further atrophy in the CA2-CA3 subfields [33]. Other studies have failed to find a significant association between the presymptomatic phase of AD and CA1 atrophy [14]. Identifying neurocognitive tests that are specifically associated with these regions in the presymptomatic phase (i.e. even before MCI diagnosis) will serve as attainable and inexpensive

measures in clinical settings that will conveniently help target individuals at higher risks of memory impairment. We urge future research to study the sensitivity of these neurocognitive tests in relation to hippocampal subfield atrophy and to incident MCI and AD.

Although there are numerous studies that have investigated the association between total hippocampal volume and neurocognitive tests, research on associations between hippocampal subfields and neurocognitive measures are sparse. In one study Lim and colleagues [34], reported associations between atrophy in the CA1 and subiculum and verbal immediate recall, verbal delayed recall, verbal recognition memory, and constructional recall in 51 AD patients [34]. In another study, investigating hippocampal atrophy and onset of dementia, Costafreda et al. [35] found that by analyzing the level of hippocampal atrophy alone the authors accurately categorized participants into MCI vs no MCI groups. Hippocampal morphology in MCIs was also associated with poorer global cognition (MMSE) and verbal memory (CERAD memory). In their study, CA1 was the area most specifically associated with risk of MCI conversion after 12 months of follow-up [35]. Although our study was cross-sectional, and thus we were unable to find out rates of conversion based on HC atrophy and neurocognitive tests, our findings are consistent with previous literature reporting CA1 and subiculum's specific involvement in visual and verbal episodic memory in older adults.

Despite novel results, our study has some noteworthy limitations. Within the hippocampus itself, the subfields are not distinctively separated, and due to their proximity some subfield boundaries in FreeSurfer, such as CA1 and the subiculum may have some overlap since it is possible that some areas of the CA1 may also be assigned to the subiculum and CA2/CA3 [26,36]. In fact, FreeSurfer's accuracy in detecting some of the hippocampal subfields has been questioned [36], therefore further studies using manual methods or newer automated methods are warranted to confirm our findings. We applied Sidak correction for multiple testing; like most other adjustments for multiple comparisons, this test can be somewhat conservative; the correction may also lead to false negatives, hence reducing statistical power. Due to the high correlations ($r = 0.37$) between FCSRT delayed recall and Complex Figure delayed recall, the association between these tests and CA1 and subiculum may be reflective of the variance between the cognitive tests. Although the number of subjects in this study is fairly large in comparison with other MRI studies, some of the associations marginally missed significance (CA1 and FCSRT Delayed Recall, $p = 0.025$), therefore larger population-based studies might be required to detect smaller associations. The cross-sectional nature of this study precludes conclusions about causality between imaging measures and the performance on visual and verbal tests and MCI/AD incidence. Further longitudinal studies are required to investigate these associations over time and to find out whether these verbal and visual tests have the same power in predicting MCI and AD as CA1 and subiculum atrophy. We only used single tests to represent verbal and visual episodic memory; we urge other researchers to explore these associations with other tests representing these domains to generalize findings to visual and verbal episodic memories.

5. Conclusion

In this study we explored associations between delayed visual and verbal recall measures using the RBANS Complex Figure subtest and the FCSRT Delayed Recall subtest and hippocampal sub-regions in healthy older adults. Our results showed CA1 and subiculum subfields as strongly associated with both verbal and visual episodic memory. Our results suggested that hippocampal atrophy, specif-

ically, CA1 and subiculum may be markers of normative cognitive decline, and that the R-BANS Complex Figure and the FCSRT delayed recall may provide quick, sensitive insights into the aging brain and its cognitive function.

Our results offer clinical applicability by encouraging the use of these neurocognitive tests as prognostic measures in clinical settings to encourage watchful waiting in individuals whose scores are below age-adjusted means, and thus denote risk or even possible impairment, in which case a more active approach and thorough assessment that resorts to imaging procedures as a confirmatory approach for diagnosis may proceed. We suggest future research to use these and other psychometric tests to aid in developing a better understanding of the hippocampus, its subfields, and their functions relating to cognition in humans.

Conflict of interest

AZ, EZ, MZ, ML and MK declare that there are no financial, personal, or other potential conflicts of interest. RBL serves on the editorial boards of *Neurology* and as senior advisor to Headache. He has reviewed for the NIA and NINDS, holds stock options in eNeura Therapeutics; serves as consultant, advisory board member, or has received honoraria from: Alder, Allergan, American Headache Society, Amgen, Autonomic Technologies, Avanir, Boehringer-Ingelheim, Boston Scientific, Bristol-Myers Squibb, Colucid, Dr. Reddy's, Electrocore, Eli Lilly, eNeura Therapeutics, Merck, Novartis, Pfizer, Teva, Vedanta. He receives royalties from Wolff's Headache, 8th Edition, Oxford Press University, 2009 and Informa.

Funding sources

This research was supported by the Einstein Aging Study (PO1 AG03949) from the National Institutes on Aging program; the National Institutes of Health CTSA (1UL1TR001073) from the National Center for Advancing Translational Sciences (NCATS), the Sylvia and Leonard Marx Foundation, and the Czap Foundation. Its contents are solely the responsibility of the authors and do not necessarily represent the official views of the NIH.

Statement of human rights

All procedures performed in studies involving human participants were in accordance with the ethical standards of the institutional and/or national research committee and with the 1964 Helsinki declaration and its later amendments or comparable ethical standards.

Acknowledgements

We thank the EAS research participants. We thank Charlotte Magnotta, Diane Sparracio and April Russo for assistance in participant recruitment; Betty Forro, Wendy Ramratan, and Mary Joan Sebastian for assistance in clinical and neuropsychological assessments; Michael Potenza for assistance in data management.

References

- [1] C. Van Petten, Relationship between hippocampal volume and memory ability in healthy individuals across the lifespan: review and meta-analysis, *Neuropsychologia* 42 (10) (2004) 1394–1413.
- [2] N. Burgess, E.A. Maguire, J. O'Keefe, The human hippocampus and spatial and episodic memory, *Neuron* 35 (4) (2002) 625–641.
- [3] J.R. Manns, R.O. Hopkins, L.R. Squire, Semantic memory and the human hippocampus, *Neuron* 38 (1) (2003) 127–133.
- [4] K.H. Chen, et al., Hippocampal region-specific contributions to memory performance in normal elderly, *Brain Cogn.* 72 (3) (2010) 400–407.
- [5] L.L. Eldridge, et al., A dissociation of encoding and retrieval processes in the human hippocampus, *J. Neurosci.* 25 (13) (2005) 3280–3286.

- [6] A.R. Preston, et al., High-resolution fMRI of content-sensitive subsequent memory responses in human medial temporal lobe, *J. Cogn. Neurosci.* 22 (1) (2009) 156–173.
- [7] N. Suthana, et al., Dissociations within human hippocampal subregions during encoding and retrieval of spatial information, *Hippocampus* 21 (7) (2011) 694–701.
- [8] M.M. Zeineh, et al., Dynamics of the hippocampus during encoding and retrieval of face-name pairs, *Science* 299 (5606) (2003) 577–580.
- [9] R.K. Nauer, et al., Hippocampal subfield and medial temporal cortical persistent activity during working memory reflects ongoing encoding, *Front. Syst. Neurosci.* 9 (2015) 30.
- [10] G.A. Kerchner, et al., Hippocampal CA1 apical neuropil atrophy and memory performance in Alzheimer's disease, *Neuroimage* 63 (1) (2012) 194–202.
- [11] S.G. Mueller, et al., Evidence for functional specialization of hippocampal subfields detected by MR subfield volumetry on high resolution images at 4 T, *Neuroimage* 56 (3) (2011) 851–857.
- [12] S.G. Mueller, et al., Different structural correlates for verbal memory impairment in temporal lobe epilepsy with and without mesial temporal lobe sclerosis, *Hum. Brain Mapp.* 33 (2) (2012) 489–499.
- [13] S.G. Mueller, et al., Measurement of hippocampal subfields and age-related changes with high resolution MRI at 4T, *Neurobiol. Aging* 28 (5) (2007) 719–726.
- [14] M.J. West, et al., Hippocampal neurons in pre-clinical Alzheimer's disease, *Neurobiol. Aging* 25 (9) (2004) 1205–1212.
- [15] M.J. West, et al., Differences in the pattern of hippocampal neuronal loss in normal ageing and Alzheimer's disease, *Lancet* 344 (8925) (1994) 769–772.
- [16] S.G. Travis, et al., High field structural MRI reveals specific episodic memory correlates in the subfields of the hippocampus, *Neuropsychologia* 53 (2014) 233–245.
- [17] M.J. Katz, et al., Age-specific and sex-specific prevalence and incidence of mild cognitive impairment, dementia, and Alzheimer dementia in blacks and whites: a report from the Einstein Aging Study, *Alzheimer Dis. Assoc. Disord.* 26 (4) (2012) 335–343.
- [18] C. Randolph, Repeatability Battery for the Assessment of Neuropsychological Status Manual, Psychological Corporation, San Antonio, TX, 1998.
- [19] H. Buschke, Selective reminding for analysis of memory and learning, *J. Verbal Learn. Verbal Behav.* 12 (1973) 543–550.
- [20] A. Ezzati, et al., Hippocampal subfields differentially correlate with chronic pain in older adults, *Brain Res.* 1573 (2014) 54–62.
- [21] B. Fischl, et al., Whole brain segmentation: automated labeling of neuroanatomical structures in the human brain, *Neuron* 33 (3) (2002) 341–355.
- [22] R.L. Buckner, et al., A unified approach for morphometric and functional data analysis in young, old, and demented adults using automated atlas-based head size normalization: reliability and validation against manual measurement of total intracranial volume, *Neuroimage* 23 (2) (2004) 724–738.
- [23] K. Van Leemput, et al., Automated segmentation of hippocampal subfields from ultra-high resolution In vivo MRI, *Hippocampus* 19 (6) (2009) 549–557.
- [24] S.K. Krogsrud, et al., Development of hippocampal subfield volumes from 4 to 22 years, *Hum. Brain Mapp.* 35 (11) (2014) 5646–5657.
- [25] Z. Sidak, Rectangular confidence regions for the means of multivariate normal distributions, *J. Am. Stat. Assoc.* 62 (318) (1967) 626–633.
- [26] S.M. O'Mara, et al., Roles for the subiculum in spatial information processing: memory, motivation and the temporal control of behaviour, *Prog. Neuro Psychopharmacol. Biol. Psychiatry* 33 (5) (2009) 782–790.
- [27] D.G. Amaral, C. Dolorfo, P. Alvarez-Royo, Organization of CA1 projections to the subiculum: a PHA-L analysis in the rat, *Hippocampus* 1 (4) (1991) 415–435.
- [28] L.M. de la Prida, et al., The subiculum comes of age, *Hippocampus* 16 (11) (2006) 916–923.
- [29] S.G. Travis, et al., High field structural MRI reveals specific episodic memory correlates in the subfields of the hippocampus, *Neuropsychologia* 53 (2014) 233–245.
- [30] S.A. Deadwyler, R.E. Hampson, Differential but complementary mnemonic functions of the hippocampus and subiculum, *Neuron* 42 (3) (2004) 465–476.
- [31] E.A. Maguire, K. Woollett, H.J. Spiers, London taxi drivers and bus drivers: a structural MRI and neuropsychological analysis, *Hippocampus* 16 (12) (2006) 1091–1101.
- [32] M. Bobinski, et al., Atrophy of hippocampal formation subdivisions correlates with stage and duration of Alzheimer disease, *Dementia* 6 (4) (1995) 205–210.
- [33] L.G. Apostolova, et al., Subregional hippocampal atrophy predicts Alzheimer's dementia in the cognitively normal, *Neurobiol. Aging* 31 (7) (2010) 1077–1088.
- [34] H.K. Lim, et al., Relationships between hippocampal shape and cognitive performances in drug-naïve patients with Alzheimer's disease, *Neurosci. Lett.* 516 (1) (2012) 124–129.
- [35] S.G. Costafreda, et al., Automated hippocampal shape analysis predicts the onset of dementia in mild cognitive impairment, *Neuroimage* 56 (1) (2011) 212–219.
- [36] L.E.M. Wisse, G.J. Biessels, M.I. Geerlings, A critical appraisal of the hippocampal subfield segmentation package in FreeSurfer, *Front. Aging Neurosci.* 6 (2014) 261.