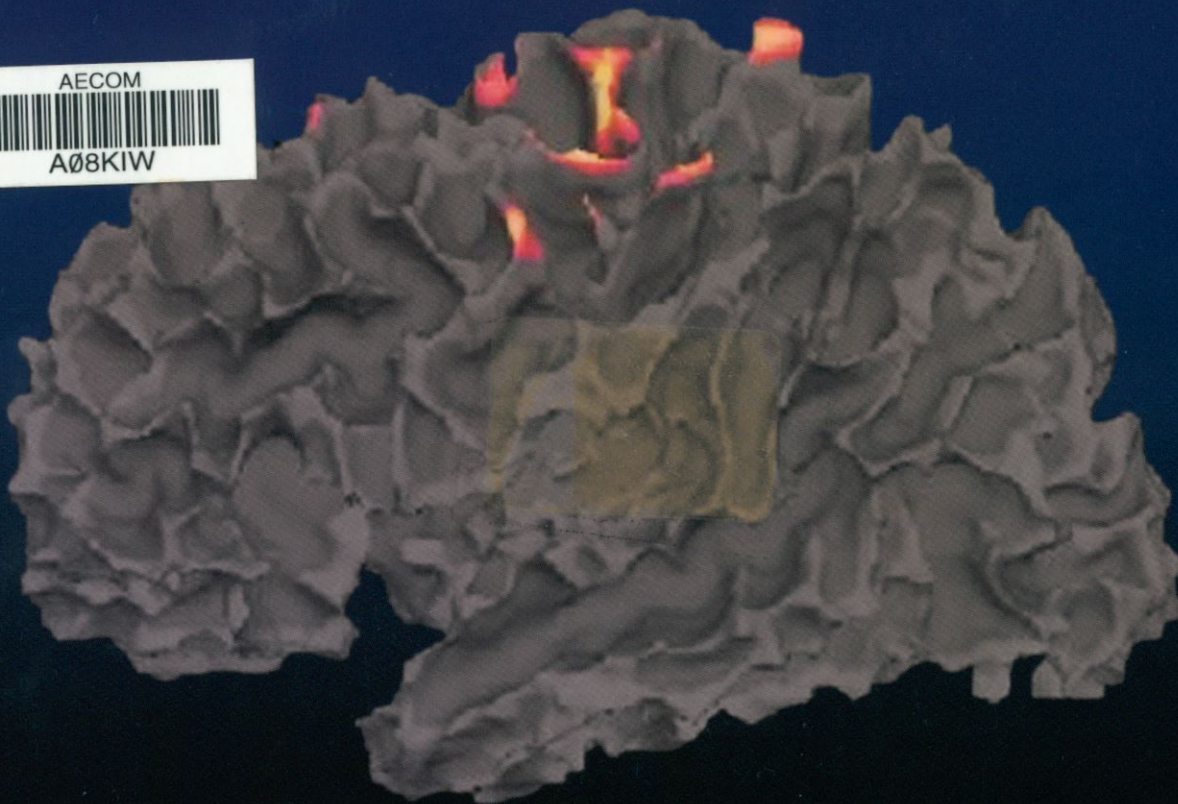
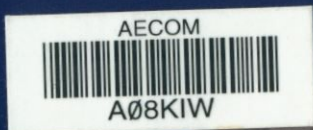

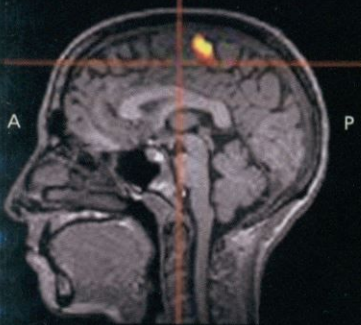
# EJBM

Volume 20 / Number 1 / 2003

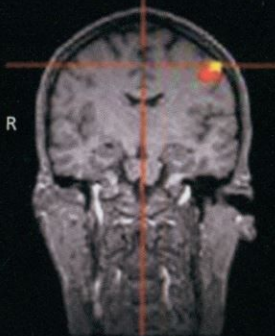
THE EINSTEIN JOURNAL OF BIOLOGY AND MEDICINE



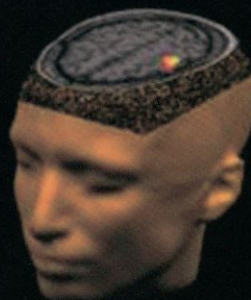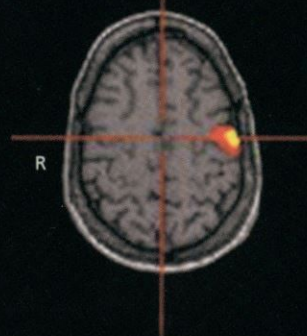
SAG



COR



TRA





# Functional Magnetic Resonance Imaging: From Acquisition to Application

Gail Yarmish\* and Michael L. Lipton\*†  
Departments of Radiology\*† and Neuroscience†  
Albert Einstein College of Medicine  
Bronx, New York 10461

## ABSTRACT

Functional magnetic resonance imaging (fMRI) is a technique that exploits magnetic resonance imaging (MRI) to detect regional brain activity through measurement of the hemodynamic response that is coupled to electrical neuronal activity. The most common fMRI method detects blood oxygen level dependent (BOLD) contrast. The BOLD effect represents alteration in the ratio of deoxygenated to oxygenated hemoglobin within brain tissue following neuronal activity. Alterations in this hemoglobin ratio result from changes in cerebral oxygen extraction, cerebral blood flow, and cerebral blood volume that occur in response to neuronal activity. The small, but detectable, change in magnetic resonance signal intensity is due to the sensitivity of magnetic resonance (MR) images to the paramagnetic deoxygenated state of hemoglobin that is the basis of contrast in fMRI applications. This review describes the physical and physiological bases of the MR signal, the principle of the BOLD effect, technical issues related to fMRI implementation, and fMRI experimental design. Research and clinical applications of fMRI are presented, including the use of fMRI in neurosurgical planning. Since it provides an individualized map of brain function, fMRI enables accurate localization of eloquent brain regions prior to surgery, allowing assessment of surgical risk and prognosis, as well as planning surgical approach.

## INTRODUCTION

Functional magnetic resonance imaging (fMRI) is a novel use of existing magnetic resonance imaging (MRI) technology that developed from experimental observations nearly a decade ago. Prior to the advent of fMRI, a structural-functional relationship underlying cognition had been determined through the localization of lesions correlated with cognitive deficits. fMRI, however, is able to demonstrate activity in distinct brain regions and neural systems while a subject performs complex tasks such as reading, memory, or spatial visualization as well as simpler motor and sensory tasks. This technology enables a more individualized mapping of brain function, which may have valuable application for preoperative neurosurgical planning, particularly in cases where potential for individual variation in location of anatomic landmarks is suspected due to the presence of local pathology.

## THE MAGNETIC RESONANCE SIGNAL

To understand the fMRI method, it is important to understand the physical basis of the magnetic resonance (MR) signal that is manipulated to form images. In a typical MRI investigation, the subject is placed into a strong and homogeneous magnetic field ( $B_0$ ). The subject becomes slightly magnetized; atomic nuclei within the subject's body that have an odd number of nucleons (atomic particles, i.e. protons and neutrons) align themselves with  $B_0$ . Signal from hydrogen atoms is detected in MRI, because they give a strong signal and are very plentiful in the body. A second magnetic field, termed the radiofrequency (RF) field, is then briefly applied (pulsed) orthogonal to  $B_0$ . This disturbs the equilibrium alignment of the protons, causing some of them to align perpendicular to  $B_0$ . The RF field is then turned off and the protons move back into alignment parallel to  $B_0$ . Two processes describe the rate at which a proton returns to parallel alignment with  $B_0$ ; these are longitudinal relaxation and transverse relaxation. The component of the subject's net magnetization that is perpendicular to  $B_0$  will induce a voltage in an appropriately positioned looped conductor. This device is called the receiver coil. The essential MR measurement is of the voltage induced in the receiver coil; the magnitude of this voltage is the MR "signal." The time after the RF is turned off, at which the operator chooses to measure this signal, will determine the extent to which relaxation affects the MR signal. This point in time is called time to echo (TE).

fMRI is predominantly concerned with effects on the rate of loss of transverse magnetization. The rate at which transverse magnetization is lost is described by the time constant  $T_2^*$ .  $T_2^*$  has two components:  $T_2$  and  $T_2'$ .  $T_2$  describes the rate of loss of transverse magnetization due to exchange of energy between nuclei, whereas  $T_2'$  describes the rate of loss of transverse magnetization due to variations in the  $B_0$  magnetic field. Small variation in the  $B_0$  field strength is caused by the local molecular environment surrounding water protons (the source of the MR signal). Hydrogen nuclei relax at different rates, depending on their local environments. For example, the  $T_2^*$  of grey matter is greater than that of white matter, reflecting the molecular environment of each tissue and the resultant variability in  $B_0$  within those tissues. As a result, the rate of transverse relaxation ( $T_2^*$ ) will vary depending on the



Functional Magnetic Resonance Imaging: From Acquisition to Application

molecular environment. These differences are evident as differences in MRI signal intensity. Thus, when the signal is measured (at TE), tissues with long  $T2^*$  will have lost less transverse magnetization and a stronger signal will be detected than in tissues with short  $T2^*$ , where signal decays more rapidly. Differences in signal detected in adjacent regions that are due to these effects of the local molecular environment form the basis of MRI contrast most relevant to fMRI (Cohen and Bookheimer, 1994).

CONTRAST IN fMRI: THE BOLD EFFECT

In fMRI applications, neuronal (electrical) activity is not observed directly. The oxidative metabolism that supports neuronal activity demands a greater supply of oxygen and glucose than in the resting state. It is the effect of changes in blood flow, blood volume, and oxygenation accompanying neuronal activation that are detected in fMRI. The first fMRI experiment was performed by Belliveau in 1991. He injected a paramagnetic contrast agent (a drug, commonly containing a chelate of gadolinium, that alters the relaxation constant (e.g.,  $T2^*$ ) of the tissue it accumulates in) intravenously and imaged the brain to show that the perception of a visual stimulus increases blood volume in the primary visual cortex (Belliveau et al., 1991). The most common fMRI technique today, however, detects changes in concentration of deoxy-hemoglobin (deoxyHb) as an endogenous contrast agent. This is referred to as "Blood Oxygen Level Dependent" or "BOLD" contrast.

Ogawa et al. (1992) was the first to note that changes in blood oxygenation can cause changes in the decay parameter,  $T2^*$ , leading to changes in image intensity in  $T2^*$ -weighted images. This effect is due to the magnetic susceptibility of different states of hemoglobin; deoxyHb is paramagnetic, while fully oxygenated hemoglobin (oxyHb) is diamagnetic. The presence of the paramagnetic deoxyHb disturbs the local magnetic field and allows for a more rapid decay of the MR signal, shorter  $T2^*$ . More deoxyHb leads to more rapid signal decay and smaller detected signal. Conversely, less deoxyHb leads to less rapid signal decay. The local  $T2^*$  measured as fMRI contrast is determined by the ratio of deoxyHb to oxyHb within a particular area of the brain. An increase in the flow of oxygenated blood to a particular region of the brain, in response to neural activation, will allow for that region to have a longer relative  $T2^*$ . This, in turn, leads to an increase in image intensity. Thus, deoxyHb is an endogenous contrast agent, and serves as the source of the signal in fMRI applications (Ogawa et al. 1992).

Immediately following neuronal activation, oxygen extraction increases immediately adjacent to the activated neurons. This leads to a change in the ratio of oxyHb to deoxyHb, favoring deoxyHb. The result is a small transient decline in signal intensity adjacent to the active brain region. This phenomenon has been observed in several laboratories conducting experiments at high field strengths (greater than 3.0 Tesla). Following the onset of activation, a concurrent increase

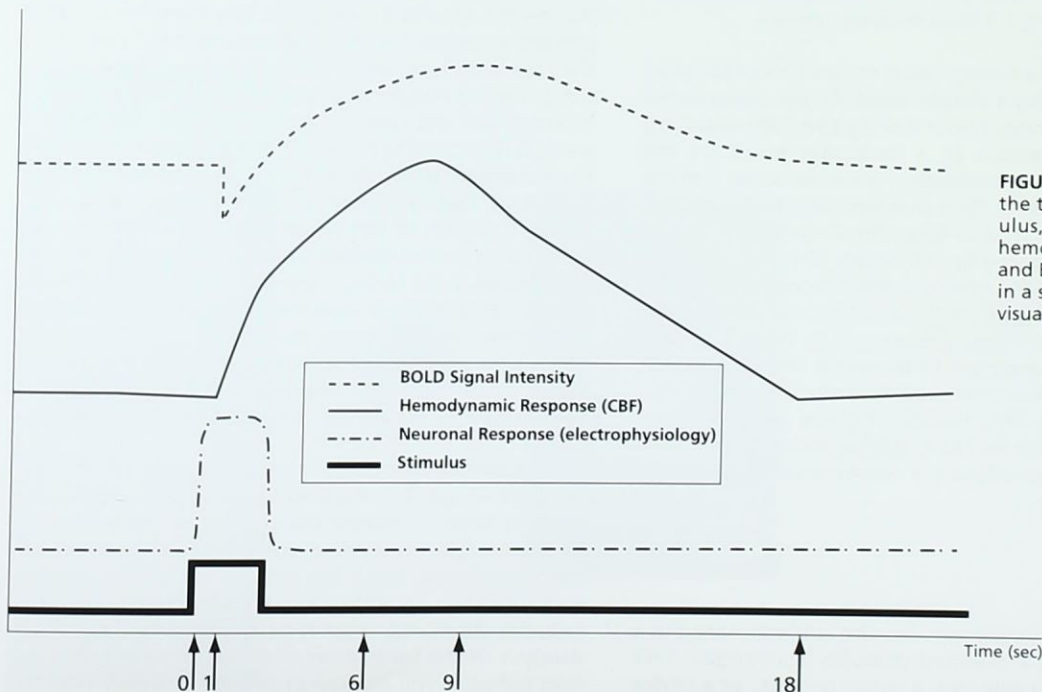


FIGURE 1 | Illustration of the time course of stimulus, neuronal activity, hemodynamic response, and BOLD signal change in a simple block design visual experiment.



Functional Magnetic Resonance Imaging: From Acquisition to Application

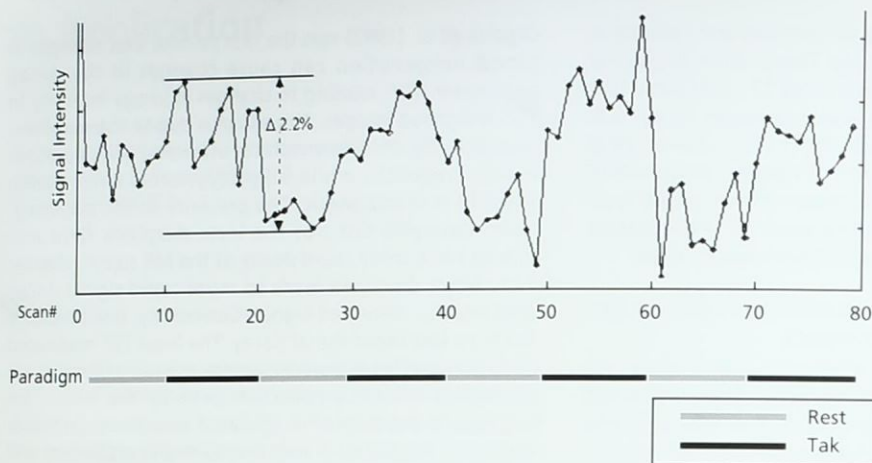


FIGURE 2 | Illustration of the time course of signal change within a region of the visual cortex in a fMRI experiment using a stimulus/task paradigm. The stimulus is a flashing red checkerboard pattern.

in cerebral blood flow (CBF) and cerebral blood volume (CBV) occurs. While it is understood that this hemodynamic response functions to provide substrate for increased neuronal metabolism, the magnitude of the hemodynamic response exceeds the degree of demand. As a result, a progressive increase in the supply of oxyHb develops over six to nine seconds following the onset of activation. This results in another change in the ratio of oxyHb to deoxyHb, now favoring oxyHb; that is, a supply of oxyHb exceeding that of the resting state. The rise in level of oxyHb relative to deoxyHb results in increased MR signal intensity relative to the resting state. This signal change occurs only in the brain region affected by the hemodynamic response to activation. The magnitude of this signal increase is generally two to three percent using 1.5 Tesla imaging systems.

Activation in the primary visual cortex (occipital lobe) can be detected by a simple block design experiment (Figure 1). Each scan taken during the fMRI scanning sequence corresponds to a particular point on the activity curve, the hemodynamic response curve, and the signal intensity curve. Note that hemodynamic response to activity occurs shortly after the stimulus is applied, because it is triggered by activation. Therefore, graphical illustration of the hemodynamic response is a similar though delayed version of the activity curve. By contrast, the actual signal intensity measured by fMRI is initially low due to the increase in deoxyHb levels. It finally increases as blood flow and therefore oxyHb levels increase. This phenomenon, known as the BOLD phenomenon, can be illustrated as a curve which is similar to the hemodynamic response curve, yet has a slight initial drop.

THE PROCESS

A typical fMRI experiment has the subject placed in a MR scanner and a planned stimulus is arranged. This may be a sensory stimulus, a cognitive task, or a motor

task. The stimulus or task is delivered or cued using specially designed apparatus (e.g., LCD video glasses, pneumatic headphones, or piezoelectric vibratory devices) that is constructed for safe use in the strong magnetic field (e.g., absence of ferromagnetic components) and to avoid interference with the MR signal acquisition (e.g., shielding of RF emissions from a video projector). Then, MR images of the subject's brain are periodically taken. First, a series of T2\*-weighted scans are taken over time; for example, one scan may be taken every 2 seconds for a total of 300 scans. Each "scan" comprises a set of images (slices) encompassing the whole brain or a specific brain region. Thus, if 30 slices are required to image the whole brain, a total of 9000 images will be generated in this short experiment. During the course of the scans, the stimulus is either present or absent (i.e., the patient alternately performs the task and then rests). This results in a "time series" comprised of images acquired during two conditions: stimulus/task and rest. The pattern of stimulus/task-rest periods is termed the stimulus/task paradigm. It is the key parameter in future analysis of the images to detect activation. The time course of signal change can be seen within a region of the visual cortex in a fMRI experiment using a stimulus/task paradigm (Figure 2). Prior to analysis of time series images for detection of brain activation, a series of tools are employed to correct for distortions in the images, to remove the effect of the subject moving his or her head during the experiment and to compensate for changes in signal intensity that are unrelated to activation (e.g., signal drift over time).

Once these preprocessing steps are completed, the time series of images is compared to the stimulus/task paradigm in order to define the regions of the brain that demonstrate differences in signal intensity between the two conditions. Since MR images are digital images, each image is an array of spatial locations (voxels or volume elements) displayed as an array of pixels. Analysis of the time series of images entails a comparison between the pattern of change in signal intensity



Functional Magnetic Resonance Imaging: From Acquisition to Application

in the image and the pattern of change in the paradigm. A separate statistical comparison (e.g., correlation, t-statistic, etc.) is made for each voxel. Although the deoxyHb effect is so small that it is typically not visible on inspection of the time-series images, it can be identified after statistical comparison of the temporal variation of signal intensity with the stimulus/task paradigm. Statistical images are then generated that identify image locations containing a pattern of signal change which is compatible with what is expected based on the paradigm. "Active" voxels are identified using a color-scale that is coded according to level of statistical significance of the correlation detected in each voxel. These statistical images are then superimposed onto high-resolution structural images in order to identify those anatomical structures in the brain that are activated by the stimulus (Figure 3).

SPATIAL FACTORS

The fMRI technique involves an inherent loss of spatial resolution. Spatial resolution is compromised because the effect that is measured in fMRI, namely the change in levels of oxy/deoxyHb, occurs predominantly in the postcapillary venous structures and may therefore be quite removed from the true site of neuronal activity. For example, the BOLD effect is detected in large veins that drain the active areas of cortex (even in the dural venous sinuses) distant from the site of cortical activity. By implication, signal changes would be detected spatially displaced from the region of neuronal activation, but detected as activation in the fMRI experiment.

Despite this limitation, fMRI has excellent spatial sensitivity as compared to other functional neuroimaging techniques (Cohen and Bookheimer, 1994). Further developments aimed at detection of the early negative signal change, faster imaging, higher resolution imaging, and direct measurement of CBF may improve the spatial specificity of fMRI.

ADVANTAGES OF fMRI

fMRI has many advantages over other methods of mapping cortical function. First, it is noninvasive. It is therefore not associated with the risk and complications inherent in an invasive procedure such as intraoperative electrophysiological mapping. In comparison to noninvasive electrophysiology methods such as electroencephalography (EEG), event related potential (ERP), and magnetoencephalography (MEG), fMRI has far superior spatial specificity and spatial resolution as well as the ability to concurrently map function to brain anatomy. fMRI is also quite advantageous when compared to other noninvasive cortical-mapping modalities. As compared to activation positron emission tomography (PET) studies, fMRI is widely available and does not use any radioisotopes. Moreover, PET studies have poor spatial and temporal resolution; in order to provide appropriate structural and anatomical information, they must be co-registered with MRI. In contrast, fMRI provides both structural and functional information with the same imaging modality. The capacity of fMRI to survey the entire brain makes it well suited for multi-system investigation.

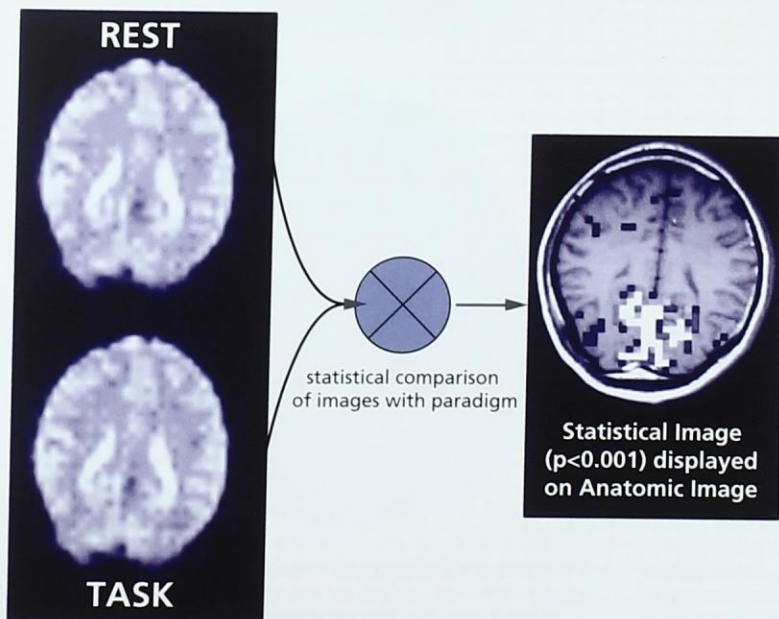
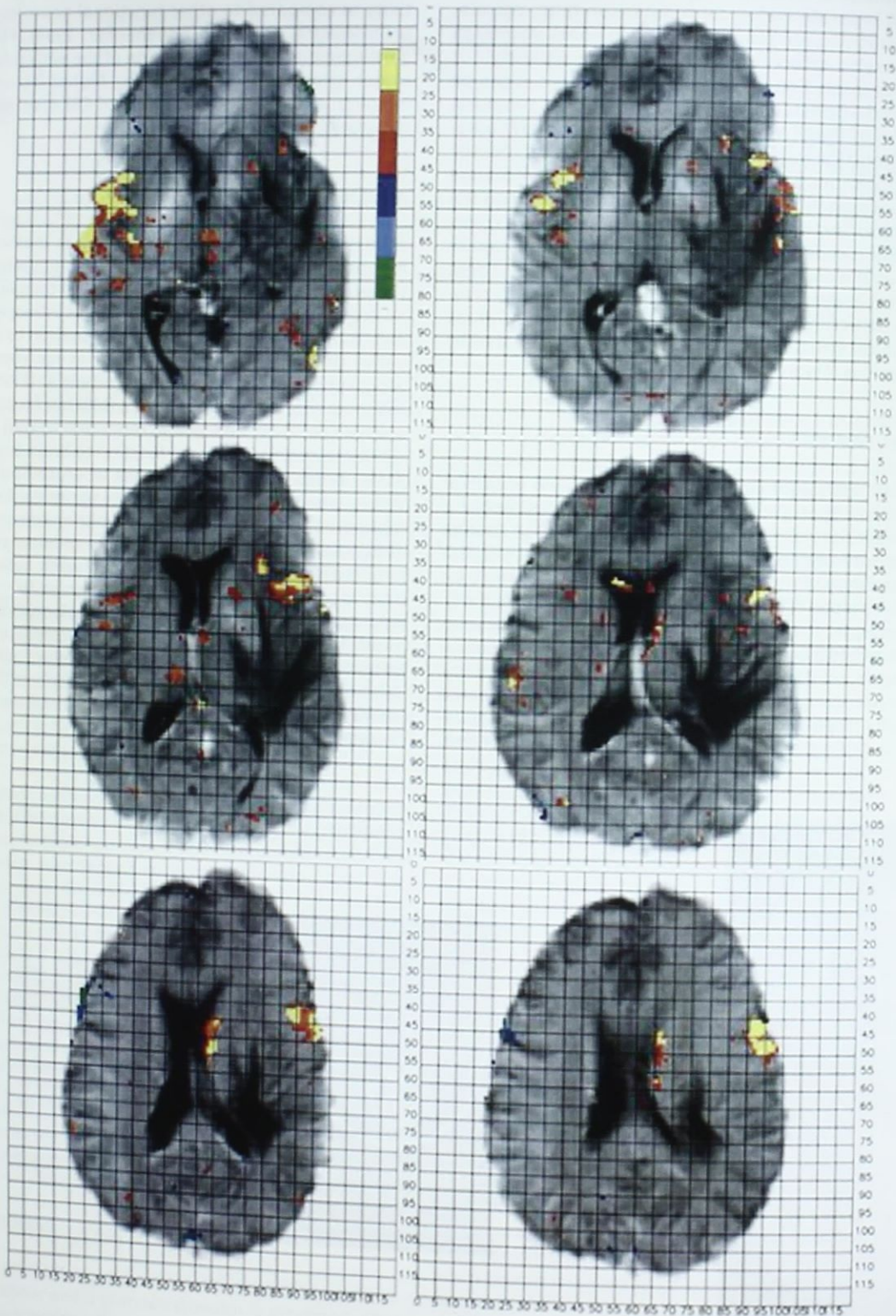


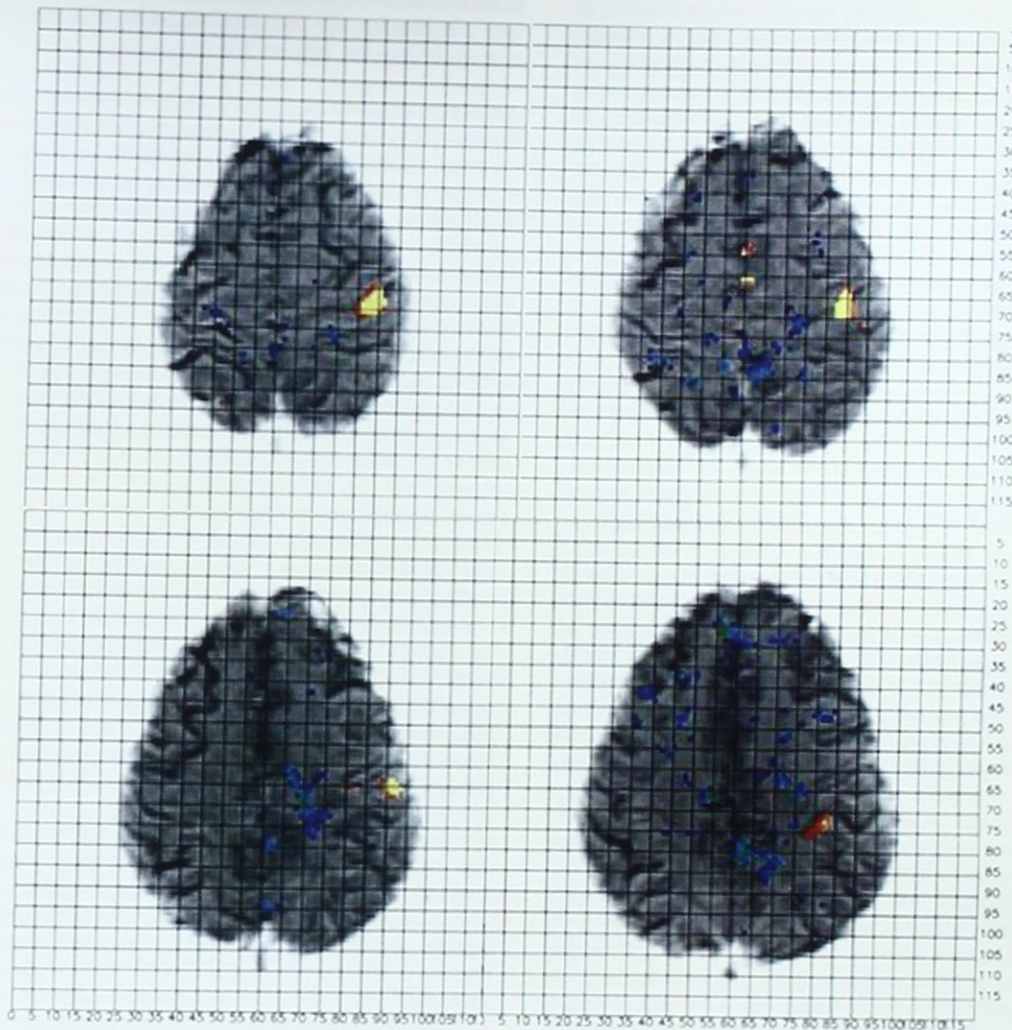
FIGURE 3 | Raw images of rest and task states, statistical comparison of these images with the paradigm, and superimposition of the statistical image onto a structural image. This process enables identification of those structures in the brain that are activated by the stimulus.



Functional Magnetic Resonance Imaging: From Acquisition to Application







**FIGURE 4** | An example of preoperative mapping using fMRI in a 27-year-old woman with a low grade glioma. She has been asked to perform an object naming task for assessment of expressive speech and delineation of the eloquent cortex. The significant activation (red-yellow) is separated from the tumor, implying low risk for damage to the language area. This patient underwent tumor resection with no postoperative language deficit.

**TECHNICAL ISSUES IN fMRI**

One of the most significant challenges in fMRI acquisition is the small size of the signal change, generally reported in the 1 to 4 percent range for imaging at 1.5 Tesla. Noise in fMRI comes from a variety of sources, including thermal noise from the subject, receiver coil, and other electronics. Possible sources of noise associated with a functional imaging study include differences in the manner in which a task is performed and neuronal events associated with behavior unrelated to the task. The apparatus used to deliver the stimulus or to cue a task may also contribute noise to the system.

The relatively small signal change associated with neural activity (approximately 2% at 1.5 Tesla) may lead to the detection of random or unrelated signal change as neural activity. For example, head motion during scanning had led to the suggestion that many apparent activation results obtained using fMRI were the result of motion artifacts (Howseman and Bowtell, 1999). Although it is now believed that this generally is not the case, the problem of motion artifacts remains an important one. Moreover, because of the need for stringent head motion control, the choice of subject responses available for measurement is limited. Experiments focused on primary sensory systems can rely on



Functional Magnetic Resonance Imaging: From Acquisition to Application

the stimulus, such as auditory input or visual flashes, to produce activation without the need for a motion response. However, it is more difficult to control for motion artifacts in motor experiments. For example, a very small movement of the head may result from hand movements, such head movement may lead to entirely false activation. Similarly, studies of higher cognitive functions such as language and memory may be severely curtailed, as speaking aloud is difficult to accomplish without significant head movement. Even after precautions are taken to minimize head movement through the use of head restraints, head movement of 1 to 2 mm during scanning is common (Howseman and Bowtell, 1999).

Several methods are used to mitigate the effects of noise on fMRI data. The most significant of these includes the use of higher field strength in fMRI acquisition, which allows for a greater intrinsic signal to noise ratio. This effect is in large part due to the fact that the magnitude of the MR signal increases with greater magnetic field strengths. Noise reduction is also due, at least in part, to the greater extent of magnetization difference between oxyHb and deoxyHb which occur at higher field strengths (Cohen and Bookheimer, 1994). Another attempt at noise mitigation in fMRI applications is the use of rapid acquisition techniques such as Echo-Planar Imaging (EPI) and spiral imaging. Rapid imaging allows physiological motion to be frozen, therefore, avoiding or minimizing data inconsistency within the image. It also permits images to be averaged, in an attempt to reduce the cumulative effect of undesired physiologic variations. EPI is currently the standard for acquisition of fMRI data. Post-processing realignment methods attempt to correct for head movement, although it cannot account for all of its effects. Whether the problem of head movement during fMRI acquisition can be completely overcome is not yet known (Howseman and Bowtell, 1999). Additional post-processing methods are used to correct for variability in image intensity not related to the task paradigm such as temporal drift of the MR signal over time.

EXPERIMENTAL DESIGN

The prototypical fMRI experimental design is categorical and blocked. In this approach, two conditions alternate over the course of a scan. It is categorical because the experiment examines two levels of a category (e.g., finger motion versus rest), and it is blocked because these periods of time often consist of a block of several trials presented together. For example, a given block might present a passively perceived visual stimulus or a sequence of words to be remembered. Experimental blocks alternate with control blocks. The control blocks are designed to evoke all of the cognitive processes present in the experimental block except for the cognitive process of interest. Using the principle of cognitive

subtraction, differences in neural activity between the two conditions can be attributed to the cognitive process of interest (Figure 3).

An alternative to the block design is event-related design. This type of design permits studying signal changes associated with individual trials as opposed to a larger unit of time comprised of a block of trials. With event-related fMRI designs, each trial may be composed of a single behavioral event or several behavioral events. The simplest type of event-related experiment schedules sequential trials distant enough in time from one another. This allows the hemodynamic response, which results from the brief period of evoked neural activity, to fully run its course. The responses to individual trials are then examined using an experimental design that allows these individual responses to be extracted. For example, the inter-trial interval can be extended to allow the response to arrive and dissipate before the next trial is given. Randomly mixing the trial types or randomizing the inter-trial interval but allowing the responses to overlap can also isolate individual responses. When this is done, variations in the signal intensity result from the summation of responses of differing sizes to the mixed trial types or from the summation of the responses to randomly timed trials. This approach to fMRI allows more flexibility in the design of fMRI paradigms and allows separation of effects based on stimulus type, response type, reaction time, and the like.

A critical step in any fMRI study is the statistical testing and result compilation. Once images have been through a variety of preprocessing stages, such as image reconstruction, distortion removal, and head motion correction, statistical analysis can be applied. The most commonly applied methods are the linear parametric including the t-test, cross-correlation, and multiple regression analysis. These methods are easy to use and can easily give measures of statistical significance, but require restrictive assumptions about the fMRI response timing and shape and about the noise characteristics. Non-linear parametric methods (e.g., ANOVA, ANCOVA, MANCOVA) are less restrictive and allow one to estimate the parameters contributing to the shape of the response. There are also non-parametric methods that do not even require assumptions about the times that the activation begins and ends (Moonen and Bandettini, 2000). Various fMRI processing software packages that incorporate both preprocessing algorithms and statistical modeling with analysis are available.

fMRI IN NEUROSURGICAL PLANNING

Since its discovery, fMRI has moved from the domain of the MRI research laboratory into the arena of clinical practice. Presently, one of the major clinical applications of fMRI is in the area of neurosurgical planning.



Functional Magnetic Resonance Imaging: From Acquisition to Application

The accurate localization and complete excision of a cerebral lesion without causing neurologic deficit is the goal of many intracranial neurosurgical procedures. An important determinant of the risk of surgery is the relationship of the lesion to functionally important or "eloquent" brain regions, as injury to these regions may cause irreversible neurologic impairment. Furthermore, when the location of the tumor is in an area with uncertain function such as an association area, it is important to precisely localize cortical function in order to avoid postoperative deficits (Figure 4). While the use of anatomic landmarks can approximate the location of many functionally important areas, individual variations occur. Moreover, the presence of local pathology such as a tumor or epileptogenic focus may alter the expected location of a functional area, accentuating the need for individualized maps of brain function in preoperative planning (Hirsch et al., 2000).

A variety of strategies have been employed to maximize the effectiveness of surgical resection while minimizing risk of injury to nearby functional cortex. The gold-standard procedure for determining where these areas begin and end is direct intraoperative electrophysiologic cortical mapping. However, this method has certain technical limitations. Direct cortical mapping requires a craniotomy under anesthesia with its associated risk and expense. Moreover, only limited regions can be tested as many areas of the brain are found along the depths of the sulci and are therefore inaccessible to stimulation. Most importantly, because this mapping is done at the time of surgery, the information obtained cannot be used preoperatively for risk assessment and surgical planning. Non-invasive cerebral mapping techniques have thus evolved to localize functionally important cortical areas prior to surgery (Hirsch et al., 2000).

It is still unclear whether fMRI can replace intraoperative mapping entirely. In fact, a recent animal study reports that the overall concordance rate between the fMRI and electrophysiologically defined maps is only 55% (Disbrow et al., 2000). Nevertheless, the fMRI exam can often survey many brain regions prior to surgery, enabling the surgeon to do a more limited invasive mapping procedure. This allows the patient to remain under anesthesia for a shorter period of time. Furthermore, preoperative fMRI also allows the risks of surgery to be more clearly defined and allows for a more accurate assessment of whether a patient is a candidate for surgery or whether some form of alternative therapy may be more appropriate.

fMRI AS A PREDICTIVE TOOL

Another potential clinical application of fMRI is the prediction of future brain function based on patterns

of brain activation which are observed during particular tasks. A recent fMRI study reported that patterns of brain activation during tasks requiring memory differ among those with differing genetic risk for Alzheimer's Disease (AD). The authors reported that there were patterns of greater activation during periods of learning or recall among carriers of the APOE 4 allele, the chief known genetic risk factor for AD, than among similar subjects who had the APOE 3 allele. These differences correlated with the degree of memory decline among subjects who were then retested two years later. This study endorsed fMRI as a powerful tool that may be used in those without any behavioral signs of disease to predict a subsequent decline in memory and risk of progression to AD (Bookheimer et al., 2000). Investigation of these and other clinical applications of fMRI are ongoing.

CONCLUSION

fMRI is capable of noninvasive isolation of many individual, simultaneous, and coordinated brain events throughout the entire three-dimensional volume of the brain. This multi-level view of brain activity will certainly enable more detailed study and enhanced understanding of brain functioning, as well as providing a safer and perhaps more accurate standard for assessing neurosurgical risk and cognitive disease states.

REFERENCES

Belliveau, J.W., Kennedy, D.N., McKinstry, R.C., Buchbinder, B.R., Weiskoff, R.M., Cohen, M.S., Vevea, J.M., Brady, T.J., and Rosen, B.R. (1991) Functional mapping of the human visual cortex by magnetic resonance imaging. *Science* 254:716-719.

Bookheimer, S.Y., Strojwas M.H., Cohen M.S., Saunders A.M., Pericak-Vance M.A., Mazziotta J.C., and Small G.W. (2000) Patterns of brain activation in people at risk for Alzheimer's disease. *New Engl. J. Med.* 343:450-456.

Cohen, M.S. and Bookheimer, S.Y. (1994) Localization of brain function using magnetic resonance imaging. *Trends Neurosci.* 17:268-277.

Disbrow, E., Slutsky, D., Roberts, T., and Krubitzer, L. (2000) Functional MRI at 1.5 tesla: a comparison of the blood oxygen level-dependent signal and electrophysiology. *Proc. Natl. Acad. Sci. USA* 97:9718-9723.

Hirsch, J., Ruge, M., Kim, K., Correa, D., Victor, J., Relkin, N., Labar, D., Krol, G., Bilsky, M., Souweidane, M., DeAngelis, L., and Gutin, P. (2000) An integrated functional magnetic resonance imaging procedure for preoperative mapping of cortical areas associated with tactile, motor, language, and visual functions. *Neurosurg.* 47:711-722.

Howseman, A.M. and Bowtell, R.W. (1999) Functional magnetic resonance imaging: imaging techniques and contrast mechanisms. *Phil. Trans. R. Soc. Lond. B.* 354:1179-1194.

Moonen, C.T.W. and Bandettini, P.A. (2000) Functional MRI. Springer-Verlag, New York. pp. 103-107, 369-379.

Ogawa, S., Tank, D.W., Menon, R., Ellermann, J.M., Kim, S., Merkle, H., and Ugurbil, K. (1992) Intrinsic signal changes accompanying sensory stimulation: functional brain mapping with magnetic resonance imaging. *Proc. Natl. Acad. Sci. USA* 89:5951-5955.